

Entrapment Neuropathy About the Foot and Ankle: An Update

Gregory Pomeroy, MD
James Wilton, DPM
Steven Anthony, DO

Abstract

Occurrences of entrapment neuropathies of the lower extremity are relatively infrequent; therefore, these conditions may be underappreciated and difficult to diagnose. Understanding the anatomy of the peripheral nerves and their potential entrapment sites is essential. A detailed physical examination and judicious use of imaging modalities are also vital when establishing a diagnosis. Once an accurate diagnosis is obtained, treatment is aimed at reducing external pressure, minimizing inflammation, correcting any causative foot and ankle deformities, and ultimately releasing any constrictive tissues.

From the New England Foot and Ankle Specialists, Mercy Hospital, Portland, ME (Dr. Pomeroy), Valley Regional Hospital, Claremont, NH (Dr. Wilton), and Advanced Orthopedic Center, Port Charlotte, FL (Dr. Anthony).

Dr. Pomeroy or an immediate family member is a member of a speakers' bureau or has made paid presentations on behalf of Stryker, is an employee of Stryker and Osteomed, and serves as a board member, owner, officer, or committee member of the New England Orthopaedic Society. Dr. Wilton or an immediate family member serves as a board member, owner, officer, or committee member of the Association of Extremity Nerve Surgeons. Neither Dr. Anthony nor any immediate family member has received anything of value from or has stock or stock options held in a commercial company or institution related directly or indirectly to the subject of this article.

J Am Acad Orthop Surg 2015;23:58-66

<http://dx.doi.org/10.5435/JAAOS-23-01-58>

Copyright 2014 by the American Academy of Orthopaedic Surgeons.

Nerve entrapment of the lower leg, ankle, and foot is relatively uncommon. Variable anatomy produces a spectrum of symptoms and diagnostic findings. Any of the five major nerves (tibial, deep peroneal, superficial peroneal, sural, saphenous) and their branches may become entrapped at various locations. To establish an accurate diagnosis, physicians must rely on a comprehensive physical examination and a thorough understanding of the relevant anatomy. Anatomic studies have helped identify specific areas in which nerves are commonly compressed. Advanced imaging, including MRI and ultrasonography, and nerve conduction velocity (NCV) studies have improved the ability to localize the area of entrapment. When an entrapment is diagnosed and localized, effective treatment is aimed at removing any external compressive factors, decreasing inflammation and edema, correcting any deformities or osseous abnormalities, and ultimately releasing any tissues compressing the affected nerve.

Tarsal Tunnel Syndrome

Tarsal tunnel syndrome is an entrapment neuropathy of the tibial

nerve as the nerve passes posterior to the medial malleolus and medial to the talus and calcaneus. The term is also sometimes used to describe entrapment of any of the major terminal branches after they leave the tarsal tunnel proper. The tibia forms the anterior wall of the tunnel, the talus and the calcaneus form the lateral wall, and the flexor retinaculum forms the roof. In most patients, the tibial nerve divides into three terminal branches (ie, medial plantar nerve, lateral plantar nerve, medial calcaneal nerve) within the tarsal tunnel.¹

Tarsal tunnel entrapment may be divided into proximal and distal syndromes; a proximal syndrome is compression of the tibial nerve, and a distal syndrome implies compression of one or more of the terminal branches.² In most persons, the nerve branches within the tunnel; therefore, distal compressions may be the result of compression within the tarsal tunnel proper or compression distal to the tunnel as the terminal branches traverse the fascial planes of the foot. Distal entrapments outside the tarsal tunnel include compression of the medial plantar nerve (ie, jogger's foot) and compression of the first branch of

the lateral plantar nerve (ie, Baxter nerve).

Proximal Tarsal Tunnel

The tibial nerve is most commonly compressed in the tarsal tunnel proper. Space-occupying lesions have been identified with tarsal tunnel syndrome, including tenosynovitis, ganglion, lipoma, venous engorgement, neurilemmoma, exostosis, and accessory musculature within the canal.³ Other etiologies include bony or cartilaginous prominences, trauma, and fibrosis or thickening of the flexor retinaculum.⁴ It also is the senior author's experience that significant hindfoot pronation may place excessive tension on the nerve.

Patients typically report diffuse pain along the medial ankle and plantar foot. The pain may be exacerbated by activity and alleviated by rest. Symptoms are often present at night. Patients may have difficulty describing the nature of the pain, but they typically characterize it as burning, shooting, tingling, numbing, or electric. These same symptoms may radiate proximally into the calf (ie, Valleix phenomenon) or radiate distally in the distribution of any and all terminal branches of the tibial nerve.^{5,6} Intermittent numbness in the plantar foot also may be present. A positive Tinel sign may often be elicited, and patients may report pain with deep palpation in the area of the tarsal canal. The dorsiflexion-eversion test may also reproduce symptoms.⁷

Radiographs and MRI or ultrasonography should be used to identify any bony or soft-tissue etiologies. Ultrasonography is reliable and cost effective in some studies, but the results are operator dependent.^{2,8} Electrodiagnostic studies are recommended to rule out more proximal nerve pathology (ie, double crush syndrome) or underlying neuropathy or myopathy.⁹ Electrodiagnostic studies are also

used to confirm entrapment and may be considered as a supplement to a careful and precise history and physical examination; however, they cannot be used exclusively to rule in or rule out tarsal tunnel syndrome. Electromyography (EMG) studies have been shown to have a high false-positive rate when used for testing the intrinsic muscles of the foot, and NCV studies have been shown to have a high false-negative rate.^{10,11} Patel et al¹² conducted an evidence-based review of electrodiagnostics in tarsal tunnel syndrome and concluded that sensory NCV may be more likely to be abnormal than motor NCV, but the true sensitivities and specificities of these tests are unknown.¹²

Nonsurgical management is typically attempted before surgical intervention. The mainstays of nonsurgical care are anti-inflammatory medication, activity modifications, night splinting, physical therapy, and discontinuation of the use of any compressive clothing or footwear. Corticosteroid injections may provide short-term relief, but supportive evidence is lacking to recommend these treatments.

Surgical release of the tibial nerve and its terminal branches is recommended when nonsurgical measures fail. The entire flexor retinaculum should be released. An incomplete release has been shown to be a cause for continued pain after surgery.¹³ Distal release of the tunnels of the medial plantar, lateral plantar, and calcaneal nerves is also advocated and should be considered.⁹

Other independent factors that may affect outcomes are the cause of the compression and the timing of surgery.^{4,6,14-16} If the symptoms are secondary to a space-occupying lesion, resection may lead to improved outcomes compared with those of patients who have no identifiable lesion.^{14,15} Sammarco and Chang⁶ reported on 75 patients; these authors noted improvements in foot scores and better outcomes in patients who

had had symptoms for <1 year. Takakura et al¹⁶ suggested that recovery of the nerve was poor when decompression was delayed, whereas early diagnosis and intervention resulted in an excellent prognosis. Potential complications with release of the tarsal tunnel may include continued symptoms secondary to an incomplete release, or abundant scar formation, wound complications, and iatrogenic neurovascular injury.^{13,14}

Jogger's Foot

The medial plantar nerve may be compressed between the abductor hallucis fascia and its origin at the navicular and calcaneus, between the abductor hallucis muscle belly and the knot of Henry, or as it passes through the medial intermuscular septum.^{17,18} Patients report exercise-induced pain on the medial plantar surface of the foot. The pain often radiates distally to the plantar surface of the first, second, and third toes and may radiate proximally into the medial heel and ankle. Long-distance runners with valgus hindfeet may be more susceptible to jogger's foot.¹⁷

Physical examination findings include a positive Tinel sign at the plantar border of the navicular tuberosity and dysesthesias along the heel, medial arch, and first through third toes. Patients may have hindfoot valgus and pes planus. Their shoe wear should be examined for any sources of external compression (eg, excessive or rigid arch support).¹⁷ Radiographs may be used to rule out bony abnormalities and to assist in diagnosing causative deformities of the foot. MRI findings may include space-occupying lesions and denervation edema of the affected muscles.¹⁸

Initial nonsurgical management is similar to the care provided for proximal tarsal tunnel syndrome. If these modalities fail to provide relief, surgical release should be considered.

Figure 1

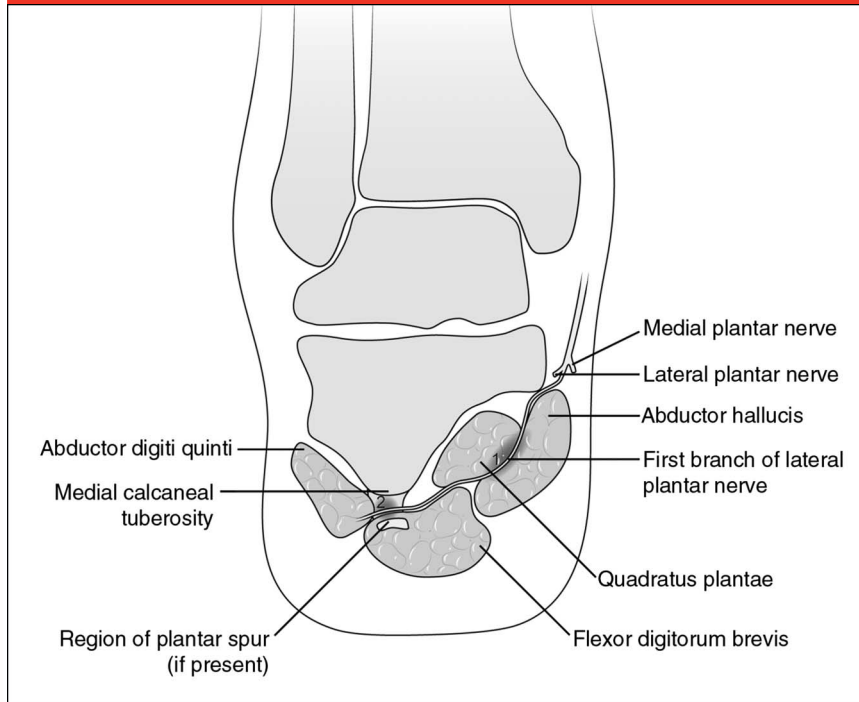


Illustration showing a coronal view of the hindfoot and demonstrating two areas (1, 2) of possible impingement of the first branch of the lateral plantar nerve (ie, Baxter nerve). (Reproduced from Lareau CR, Sawyer GA, Wang JH, DiGiovanni CW: Plantar and medial heel pain: Diagnosis and management. *J Am Acad Orthop Surg* 2014;22[6]:372–380.)

The deep fascia of the abductor hallucis should be released from its origin on the calcaneus to the knot of Henry. Consideration should be given to extending the release proximally to include the flexor retinaculum and the tibial nerve because this branch may be compressed distally or within the tarsal tunnel proper.^{1,2}

Baxter Neuropathy

Entrapment of the first branch of the lateral plantar nerve was initially described by Baxter and Thigpen.¹⁹ It typically occurs between the fascia of the abductor hallucis and the quadratus plantae muscles, but it may also occur between the flexor digitorum brevis muscle and the calcaneus.^{19,20} Multiple etiologic factors have been proposed, including stretching of the nerve in running athletes, muscle hypertrophy, bone spurs, and bursitis

and inflammation about the plantar fascia origin^{19,20} (Figure 1).

Compression of the first branch of the lateral plantar nerve presents as chronic medial plantar heel pain, frequently similar in location to that of plantar fasciitis. However, in contrast to plantar fasciitis, symptoms are more proximal and medial, tend to worsen with activity, and may be exacerbated with eversion and abduction of the foot.²⁰ The pain may also radiate proximally into the medial ankle or distally and laterally across the plantar foot. Paresthesias and weakness are not typically reported. On physical examination, the most common finding is tenderness over the nerve deep to the abductor hallucis. Palpation of this area should reproduce symptoms and may cause radiation of the pain proximally or distally.¹⁹ More proximal or distal sites of entrapment should be ruled out with palpation.

Further diagnostic studies may be beneficial if the diagnosis is unclear. Plain radiographs may reveal underlying bony and structural abnormalities, and electrodiagnostic studies may assist with confirming the diagnosis and determining the exact location of the compression.¹² These modalities, used in conjunction with a careful history and physical examination, may reveal a more proximal nerve injury or may help rule out an underlying neuropathy or myopathy. Atrophy of the abductor digiti minimi on MRI has been suggested as a possible sign of entrapment.^{18,21,22} However, fatty atrophy of the abductor digiti minimi on MRI is also prevalent in patients with no entrapment.^{21,22}

Surgical intervention is often required. The recommended treatment is complete neurolysis by first releasing the proximal deep fascia of the abductor hallucis muscle. The nerve is then followed distally and released from any entrapment caused by the medial plantar fascia or the flexor digitorum brevis at their insertion to the calcaneus. If there is an impinging bone spur in this area, a small portion may be removed if necessary, but removing the entire spur is not recommended because this action may lead to adverse outcomes.¹⁹ Sinaeve and Vandeputte²³ reported excellent outcomes using this technique for recalcitrant inferomedial heel pain. They performed a partial release of the medial plantar fascia in all patients and performed a partial resection of an impinging bone spur in 61% of patients.²³

Soleal Sling Syndrome

Soleal sling syndrome refers to the entrapment of the tibial nerve in the proximal leg by a fibrous sling at the origin of the soleus muscle²⁴ (Figure 2). Patients may report calf pain and have symptoms similar to those of tarsal tunnel syndrome; it is not uncommon

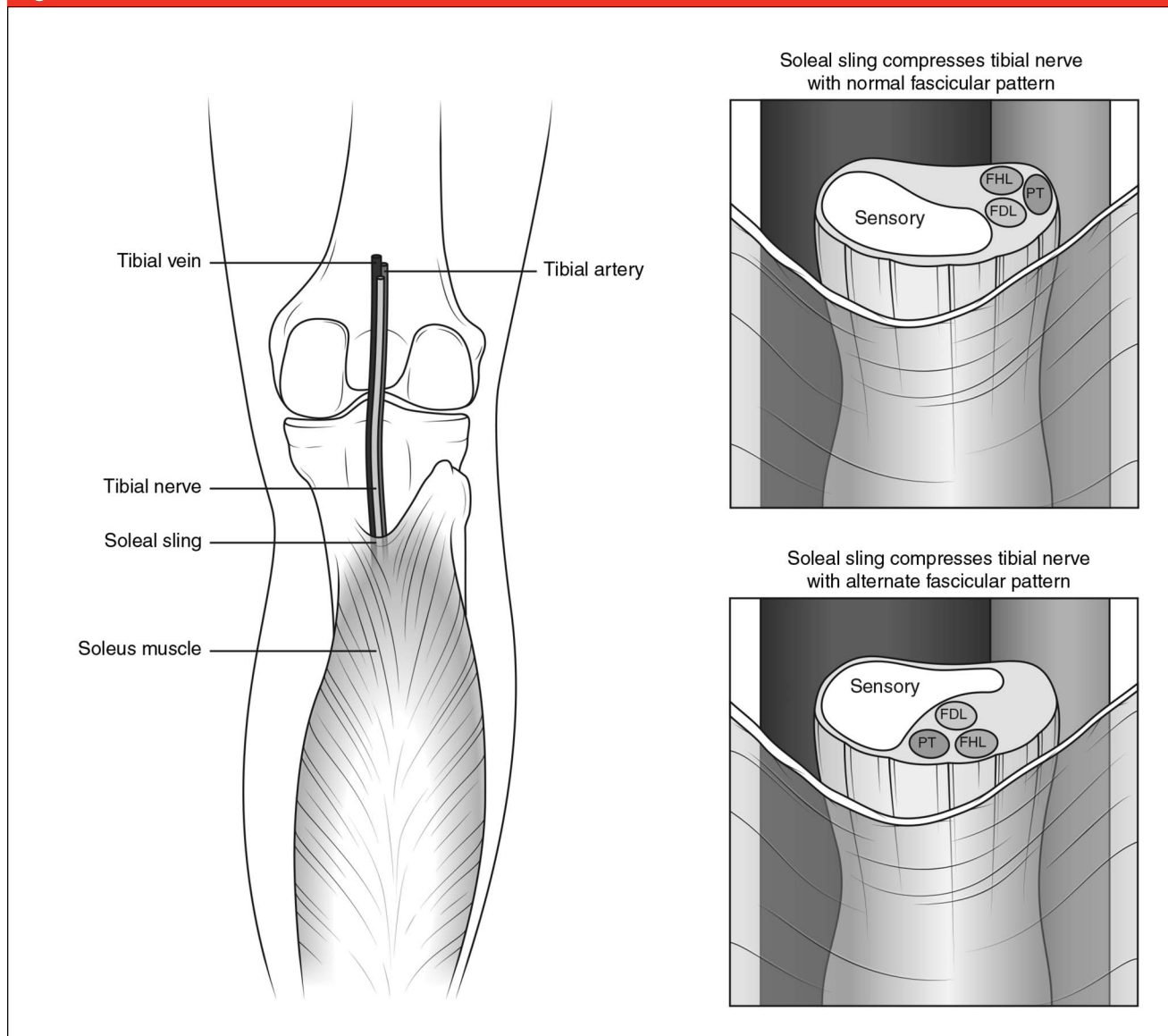
Figure 2

Illustration showing a coronal view of the proximal leg and demonstrating the tibial nerve passing deep to the fibrous soleal sling, connecting the proximal fibular and tibial origins of the soleus. FDL = flexor digitorum longus, FHL = flexor hallucis longus, PT = posterior tibialis

for patients to have a history of a failed tarsal tunnel release.²⁵ As such, the differential diagnosis of patients with a failed tarsal tunnel syndrome must include the soleal sling syndrome.^{25,26}

Physical examination typically generates pain with gentle palpation of the posterior calf at the level of the soleal sling, approximately 9 cm below the popliteal flexion crease.²⁴ This

symptom is critical for making this diagnosis. Patients may have sensory changes anywhere along the distribution of the tibial nerve. Weakness also may be present, especially in the flexor hallucis longus. NCV studies and EMG are difficult to perform because of the depth of the nerve at this level and have shown little benefit, except when they are used to rule out peripheral neuropathy and more

proximal or distal nerve compression.^{25,26} Newer high resolution (ie, 3 T) MRI and magnetic resonance neurography protocols may be beneficial in confirming the diagnosis.²⁵⁻²⁷

Nonsurgical management should consist of modification of pain-inducing activities and discontinued use of restrictive clothing or boots. Anti-inflammatory medications and nerve-modulating medications may

also be of some benefit. When non-surgical management fails to provide relief, surgical decompression is recommended. An open release of the tibial nerve at the soleal sling and the freeing of any other constrictive tissues from the nerve have shown promising outcomes with no major complications.^{25,26}

Morton Neuroma

Morton neuroma is an entrapment neuropathy of the interdigital nerve near the distal edge of the intermetatarsal ligament, most commonly in the third web space and only occasionally in the second web space. Thus, the diagnosis of second metatarsophalangeal (MTP) instability must be carefully considered in the setting of a second web space neuroma. The neuroma itself is a non-neoplastic lesion consisting primarily of degenerative changes and perineural fibrosis.^{28,29} It is unclear where the impingement occurs; some clinicians believe the primary source of entrapment is the intermetatarsal ligament, whereas other clinicians believe the primary source is the metatarsal heads and/or the tissues surrounding the MTP joints that compress the nerve.²⁸⁻³¹

Women are affected more than men, most likely as the result of wearing narrow-toe box shoes that compress the forefoot. Patients typically report burning or electric pain and paresthesias in the affected web space and may report the sensation of walking on a lump. On physical examination, symptoms are reproduced with direct pressure placed plantarly between the metatarsal heads, or findings indicate a positive Mulder sign. Another method of confirming the diagnosis is to verify whether the patient reports pain relief following an isolated lidocaine injection 2 cm proximal to the metatarsal head and plantar to the intermetatarsal ligament.³¹

Most patients can be diagnosed clinically, but in abnormal presentations the clinician may use radiographs, ultrasonography, and MRI to help confirm the diagnosis. Radiographs are used to rule out differential diagnoses, such as osteonecrosis, stress fracture, or arthritis at the MTP joint. Ultrasonography and MRI can both reliably identify the neuroma.^{2,18,32} However, identification of a neuroma with these modalities does not correlate with symptomatology; many asymptomatic patients may also have positive MRI or ultrasonography results.³³⁻³⁵ These tests should be used only to confirm the diagnosis after clinical suspicion, to rule out other soft-tissues masses, or to assist with injections or surgical planning; no role exists for electrodiagnostic studies.³¹

Nonsurgical management options include custom orthoses, metatarsal pads, accommodative footwear, NSAIDs, and injections. Corticosteroid injections have demonstrated unreliable results; the injections provide good short-term pain relief but little long-term improvement.^{29,36,37} Also, repeated injections of corticosteroids may result in damage to the MTP joint capsule and the plantar plate. Serial injections with an alcohol sclerosing agent are another form of management; however, the reported clinical results of this therapy have been disappointing, and there is concern for damage the injections may cause to the surrounding tissues.^{38,39}

Surgical treatment is indicated when nonsurgical management fails to provide relief. Historically, the most common surgical intervention is excision of the neuroma, typically through a dorsal approach for primary lesions.^{29,40,41} Excellent results may be achieved but are not guaranteed; studies demonstrate good outcomes in 51% to 93% of patients.^{28,29,31,41,42} Giannini et al²⁸ developed a clinical grading scale based on pain, maximum walking distance, sensation, and

the need for accommodative footwear. Using this scale, they reported that 78% of patients had good or excellent results, with only 3% having a poor outcome. However, Womack et al⁴² used the same scale and reported that only 51% of patients had good or excellent results in their series, with 40% having a poor outcome.

The most common complication is recurrence of pain as a result of inadequate nerve resection or removal of the incorrect tissue (ie, commonly the lumbrical tendon or digital artery).⁴³ To avoid these complications, some authors recommend decompression of the neuroma through an open or endoscopic approach. The outcomes of these procedures are reported to be excellent in 78% to 96% of patients.⁴⁴⁻⁴⁸ Villas et al⁴⁵ recently advocated a hybrid approach. Intraoperatively, the nerve is resected if it is found to be thickened; otherwise, the authors released only the transverse metatarsal ligament. Total relief of symptoms was achieved in 96% of patients after release and 98% after neurectomy.

Superficial Peroneal Nerve Entrapment

Entrapment of the superficial peroneal nerve (SPN) is a relatively rare cause of chronic leg pain.⁴⁹⁻⁵¹ The SPN branches from the common peroneal nerve and courses through the lateral compartment of the leg, innervating the peroneus longus and brevis muscles. However, anatomic studies have shown that the nerve may travel in the anterior compartment in 14% to 17% of patients.⁵⁰ The nerve pierces the deep fascia of the leg and becomes subcutaneous approximately 12.5 cm proximal to the tip of the lateral malleolus.⁴⁹⁻⁵¹

As the SPN pierces the deep fascia, it may become entrapped because of a thickened fascial tunnel, a fascial

defect and muscle herniation, or a soft-tissue mass, such as a lipoma.⁴⁹⁻⁵¹ This condition may also be seen in athletes who have lateral ligament deficiency or functional ankle instability, thus causing a traction injury to the SPN. Most patients report activity-related pain to the lower lateral leg and dysesthesias in the dorsum and lateral aspect of the foot. The symptoms may be elicited by inverting and plantar-flexing the ankle and by percussing the nerve as it emerges from the deep fascia.⁴⁹⁻⁵¹

The diagnosis may be made using the results of the history and the physical examination. NCV studies and EMG are unreliable and do not alter the course of treatment.⁴⁹⁻⁵¹ Radiographs may assist in diagnosing any malalignment or instability that may be generating the pain. Chronic exertional compartment syndrome should be considered on the differential diagnosis, and compartment pressure measurements may be performed as necessary. A localized injection of anesthetic at the site of maximal tenderness that results in the relief of symptoms can confirm the suspected diagnosis.⁵²

Initial management is directed at removing any external factors that may be causing compression and stabilizing any instability that may be tensioning the nerve. Surgery is rarely required; however, if required, it often involves a simple decompression of the fascia around the nerve exit point, although a complete fasciotomy of the lateral compartment may be required, especially in patients with exertional compartment syndrome.⁵¹ Rosson and Dellon⁵⁰ retrospectively reviewed 31 patients and found that 17% of the nerves were located in the anterior compartment, 26% traveled through both the anterior and lateral compartments, and only 57% were located exclusively in the lateral compartment. The authors recommended distal fascial release of the anterior compartment,

the lateral compartment, and the septum between the two compartments. Results of surgical treatment are variable and based on small retrospective studies and case reports. Better evidence is required to make specific recommendations, but the available research supports surgical decompression after failure of non-surgical management.⁴⁹⁻⁵¹

Anterior Tarsal Tunnel Syndrome

The deep peroneal nerve (DPN) runs between the tibialis anterior and the extensor hallucis longus (EHL) 5 cm above the ankle mortise. Under the superior extensor retinaculum, approximately 1 cm proximal to the ankle joint, the nerve divides into a medial branch and a lateral branch.^{18,52-54} The lateral branch courses deep to the inferior extensor retinaculum to provide motor innervation to the extensor digitorum brevis and sensation to the ankle joint and the lateral tarsal joints. The medial branch courses with the dorsalis pedis artery under the inferior extensor retinaculum and provides sensation to the first web space.^{18,52,53} Compression of the DPN and either of its branches may occur as it passes through the anterior tarsal tunnel, which is defined by the inferior extensor retinaculum superficially and the talonavicular joint capsule deeply.⁵³ Other structures passing through this tunnel include the dorsalis pedis artery and vein and the tendons of the EHL, the tibialis anterior, the extensor digitorum longus, and the peroneus tertius (Figure 3).

Patients with compression of the lateral branch of the DPN typically report dorsal foot pain radiating to the region of the lateral tarsometatarsal joints. Patients with medial nerve entrapment report pain and/or numbness to the first web space. Examination should include a thorough

evaluation of the entire DPN from behind the neck of the fibula to the first web space. The precise site of the compression may often be confirmed with a local nerve block.

Radiographic evaluation is critical in the workup because the most common causes of anterior tarsal tunnel syndrome are trauma and impingement of the nerve by osteophytes around the talonavicular joint.⁵⁴ MRI may be used if a space-occupying lesion is suspected.¹⁸ EMG may be valuable if latencies are seen in the nerve to the extensor digitorum brevis, indicating entrapment proximal to the inferior extensor retinaculum.^{52,55}

Nonsurgical management should focus on reducing any external compression, stabilizing any ankle laxity, and reducing inflammation through the use of physical therapy, bracing, shoe wear modifications, and anti-inflammatory medications. Surgical release is reserved for recalcitrant cases and should be very site specific to reduce scarring from extensive nerve dissection. The extensor retinaculum is released just enough to decompress the nerve. Complete release may lead to bowstringing of the tendons. Any osteophytes found over the ankle joint or over the dorsal edge of the talonavicular joint should be removed. If the extensor hallucis brevis tendon is compressing the nerve, it may be partially resected and transferred to the EHL.^{52,54} Dellon⁵⁴ followed 18 patients after surgical release of the deep peroneal nerve at the anterior tarsal tunnel and found that 80% of patients achieved good or excellent results at 2-year follow-up; no complications were reported.

Sural Nerve

Although rare, entrapment of the sural nerve can occur anywhere in the leg, ankle, or foot. The most common sites of compression are along the lateral border of the ankle, the

Figure 3

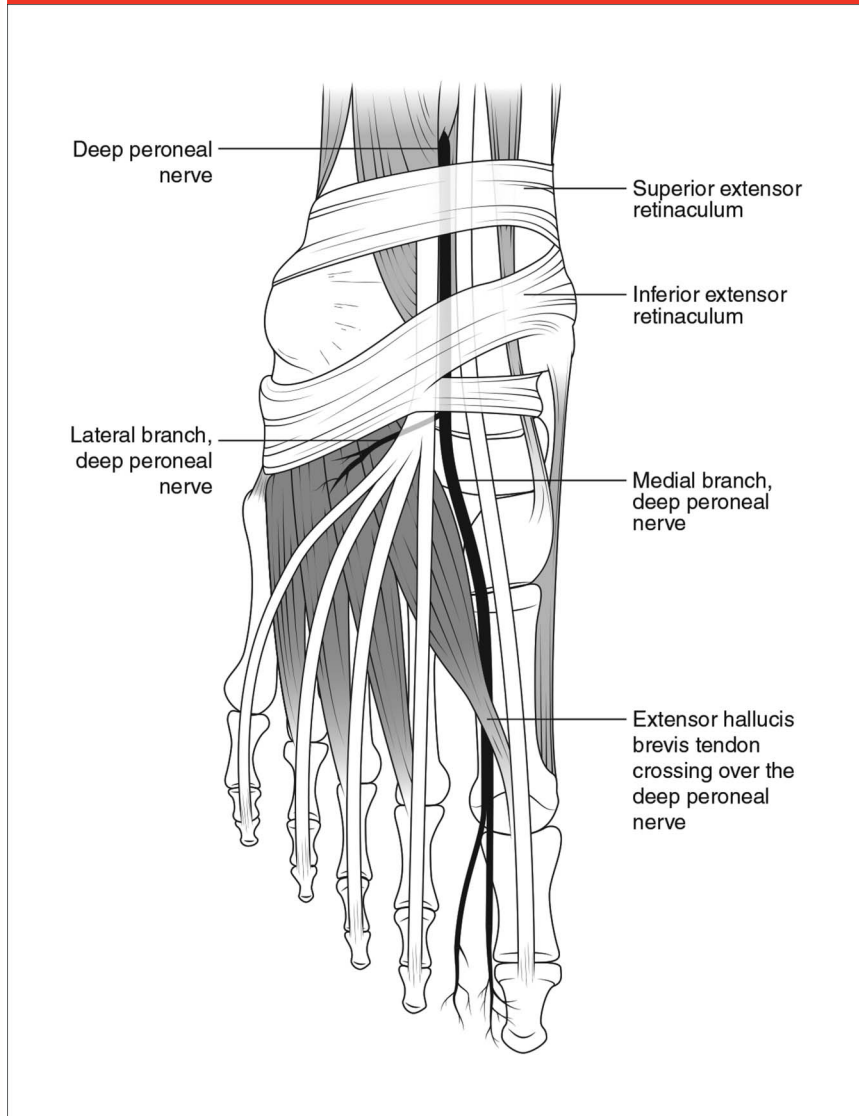


Illustration showing an anterior view of the foot and ankle and identifying the superior and inferior extensor retinacula and their relationships to the deep peroneal nerve and its medial and lateral branches.

calcaneus, and the fifth metatarsal. Entrapment is often secondary to trauma and/or surgery and the subsequent bony overgrowth, soft-tissue scarring, or instability.^{56,57} However, atraumatic entrapment of the nerve has occurred where the nerve passes through a fibrous arcade as it moves from a deep to superficial position along the lateral border of the proximal Achilles tendon.⁵⁸

Patients may report pain, burning, numbness, or aching in the postero-

lateral leg, lateral ankle, or lateral foot. Physical examination findings may include a positive Tinel sign along the course of the nerve and exacerbation of symptoms with plantar flexion and inversion of the foot.^{56,57} However, in the young athlete, the Tinel sign may be negative, and pain is often exclusive to the posterolateral leg adjacent to the musculotendinous junction of the Achilles tendon.⁵⁸

Radiographs may be used to identify bony abnormalities that are causing

impingement or structural abnormalities that may be tensioning the nerve. MRI should be considered to rule out soft-tissue masses or other space-occupying lesions that may be compressing the nerve.¹⁸ Modern NCV study protocols are reliable in confirming the diagnosis and identifying lumbosacral nerve root pathology.⁵⁶⁻⁵⁸

Treatment of sural nerve entrapment is dependent on accurately identifying the causative factors and the location of the entrapment.⁵⁸ Any underlying instability or peripheral edema should be addressed first, as should any external factors, such as constrictive shoe wear or symptom-inducing activities. Additionally, if the etiology is posttraumatic or postoperative, the authors recommend a 3- to 6-month period of observation, desensitization, and use of neural gliding techniques before proceeding to surgery. Other nonsurgical management options include anti-inflammatory medications, nerve-modulating medications, and steroid injections. Surgical intervention should address any bony abnormalities, deformities, or joint instability. If no causative factor is identified, efforts should be directed at establishing the exact location of the entrapment. The nerve may then be released from the constrictive tissue, or a nerve resection may be performed. Fabre et al⁵⁸ reported their outcomes after surgical release of the sural nerve on 18 limbs in 13 athletes. Twelve of the 13 patients were satisfied with the results and were able to return to sport at the same level. The only complications reported were a superficial hematoma in one patient and continued pain in another.⁵⁸

Saphenous Nerve

Entrapment of the saphenous nerve about the foot and ankle is also rare. Typically, entrapment occurs more proximally, but patients often present with pain and paresthasias to the foot

and ankle.⁵² In the authors' experience, distal entrapment is frequently secondary to trauma and/or surgery.

The diagnosis may be made clinically; however, radiographs, CT, and/or MRI should be considered to rule out bony or soft-tissue obstructions. NCV studies are not reliable. Buschbacher⁵⁹ reported that the saphenous nerve could not be elicited bilaterally in 25% of asymptomatic patients. Like other entrapments, however, NCV studies may be used to rule out more proximal impingement at the femoral nerve or at the lumbar nerve roots.

Surgical intervention should be delayed until it is determined that non-surgical management options have failed to provide relief. The surgeon should then consider decompression, neurolysis, or neurectomy. Decompression and neurolysis may be the preferred options because neurectomy inevitably leads to permanent sensory deficits.

Summary

Entrapment neuropathies about the lower leg, ankle, and foot are uncommon but must be considered by the orthopaedic surgeons when treating patients with lower extremity pain. Patients often present with chronic pain that has failed to respond to nonsurgical management. A detailed knowledge of the relevant anatomy is essential to establishing an accurate diagnosis, followed by initiation of appropriate treatment. Patients often respond to nonsurgical measures; however, when these modalities fail to provide relief, surgical release should be considered. The success of surgery is dependent on an accurate diagnosis, identification of the location of the entrapment, and complete release of the offending tissues.

References

Evidence-based Medicine: Levels of evidence are described in the table of

contents. In this article, references 6, 7, and 39 are level II studies. References 1, 4, 8-10, 13-17, 19, 20, 23, 25, 27-29, 32, 33, 36-38, 42-51, 54, and 56-58 are level IV studies. References 2, 5, 12, 18, 31, 40, 41, 52, and 55 are level V expert opinion.

References printed in **bold type** are those published within the past 5 years.

1. Singh G, Kumar VP: Neuroanatomical basis for the tarsal tunnel syndrome. *Foot Ankle Int* 2012;33(6):513-518.
2. Lopez-Ben R: Imaging of nerve entrapment in the foot and ankle. *Foot Ankle Clin* 2011;16(2):213-224.
3. Frey C, Kerr R: Magnetic resonance imaging and the evaluation of tarsal tunnel syndrome. *Foot Ankle* 1993;14(3):159-164.
4. Baba H, Wada M, Annen S, Azuchi M, Imura S, Tomita K: The tarsal tunnel syndrome: Evaluation of surgical results using multivariate analysis. *Int Orthop* 1997;21(2):67-71.
5. Radin EL: Tarsal tunnel syndrome. *Clin Orthop Relat Res* 1983;181:167-170.
6. Sammarco GJ, Chang L: Outcome of surgical treatment of tarsal tunnel syndrome. *Foot Ankle Int* 2003;24(2):125-131.
7. Kinoshita M, Okuda R, Morikawa J, Jotoku T, Abe M: The dorsiflexion-eversion test for diagnosis of tarsal tunnel syndrome. *J Bone Joint Surg Am* 2001;83(12):1835-1839.
8. Nagaoka M, Matsuzaki H: Ultrasonography in tarsal tunnel syndrome. *J Ultrasound Med* 2005;24(8):1035-1040.
9. Schon LC, Glennon TP, Baxter DE: Heel pain syndrome: Electrodiagnostic support for nerve entrapment. *Foot Ankle* 1993;14(3):129-135.
10. Mullick T, Dellon AL: Results of decompression of four medial ankle tunnels in the treatment of tarsal tunnels syndrome. *J Reconstr Microsurg* 2008;24(2):119-126.
11. Falck B, Alaranta H: Fibrillation potentials, positive sharp waves and fasciculation in the intrinsic muscles of the foot in healthy subjects. *J Neurol Neurosurg Psychiatry* 1983;46(7):681-683.
12. Patel AT, Gaines K, Malamut R, Park TA, Toro DR, Holland N; American Association of Neuromuscular and Electrodiagnostic Medicine: Usefulness of electrodiagnostic techniques in the evaluation of suspected tarsal tunnel syndrome: An evidence-based review. *Muscle Nerve* 2005;32(2):236-240.
13. Skalley TC, Schon LC, Hinton RY, Myerson MS: Clinical results following revision tibial nerve release. *Foot Ankle Int* 1994;15(7):360-367.
14. Pfeiffer WH, Cracchiolo A III: Clinical results after tarsal tunnel decompression. *J Bone Joint Surg Am* 1994;76(8):1222-1230.
15. Nagaoka M, Satou K: Tarsal tunnel syndrome caused by ganglia. *J Bone Joint Surg Br* 1999;81(4):607-610.
16. Takakura Y, Kitada C, Sugimoto K, Tanaka Y, Tamai S: Tarsal tunnel syndrome: Causes and results of operative treatment. *J Bone Joint Surg Br* 1991;73(1):125-128.
17. Rask MR: Medial plantar neurapraxia (jogger's foot): Report of 3 cases. *Clin Orthop Relat Res* 1978;134:193-195.
18. Donovan A, Rosenberg ZS, Cavalcanti CF: MR imaging of entrapment neuropathies of the lower extremity: Part 2. The knee, leg, ankle, and foot. *Radiographics* 2010;30(4):1001-1019.
19. Baxter DE, Thigpen CM: Heel pain: Operative results. *Foot Ankle* 1984;5(1):16-25.
20. Davis PF, Severud E, Baxter DE: Painful heel syndrome: Results of nonoperative treatment. *Foot Ankle Int* 1994;15(10):531-535.
21. Recht MP, Grooff P, Ilaslan H, Recht HS, Sfera J, Donley BG: Selective atrophy of the abductor digiti quinti: An MRI study. *AJR Am J Roentgenol* 2007;189(3):W123-W127.
22. Chundru U, Liebeskind A, Seidelmann F, Fogel J, Franklin P, Beltran J: Plantar fasciitis and calcaneal spur formation are associated with abductor digiti minimi atrophy on MRI of the foot. *Skeletal Radiol* 2008;37(6):505-510.
23. Sinnaeve F, Vandeputte G: Clinical outcome of surgical intervention for recalcitrant infero-medial heel pain. *Acta Orthop Belg* 2008;74(4):483-488.
24. Williams EH, Williams CG, Rosson GD, Dellon LA: Anatomic site for proximal tibial nerve compression: A cadaver study. *Ann Plast Surg* 2009;62(3):322-325.
25. Williams EH, Rosson GD, Hagan RR, Hashemi SS, Dellon AL: Soleal sling syndrome (proximal tibial nerve compression): Results of surgical decompression. *Plast Reconstr Surg* 2012;129(2):454-462.
26. Chhabra A, Williams EH, Subhawong TK, et al: MR neurography findings of soleal sling entrapment. *AJR Am J Roentgenol* 2011;196(3):W290-W297.
27. Chhabra A, Williams EH, Wang KC, Dellon AL, Carrino JA: MR neurography of neuromas related to nerve injury and

- entrapment with surgical correlation. *AJNR Am J Neuroradiol* 2010;31(8):1363-1368.
28. Giannini S, Bacchini P, Ceccarelli F, Vannini F: Interdigital neuroma: Clinical examination and histopathologic results in 63 cases treated with excision. *Foot Ankle Int* 2004;25(2):79-84.
29. Mann RA, Reynolds JC: Interdigital neuroma: A critical clinical analysis. *Foot Ankle* 1983;3(4):238-243.
30. Kim JY, Choi JH, Park J, Wang J, Lee I: An anatomical study of Morton's interdigital neuroma: The relationship between the occurring site and the deep transverse metatarsal ligament (DTML). *Foot Ankle Int* 2007;28(9):1007-1010.
31. Peters PG, Adams SB Jr, Schon LC: Interdigital neuralgia. *Foot Ankle Clin* 2011;16(2):305-315.
32. Musson RE, Sawhney JS, Lamb L, Wilkinson A, Obaid H: Ultrasound guided alcohol ablation of Morton's neuroma. *Foot Ankle Int* 2012;33(3):196-201.
33. Symeonidis PD, Iselin LD, Simmons N, Fowler S, Dracopoulos G, Stavrou P: Prevalence of interdigital nerve enlargements in an asymptomatic population. *Foot Ankle Int* 2012;33(7):543-547.
34. Bencardino J, Rosenberg ZS, Beltran J, Liu X, Marty-Delfaut E: Morton's neuroma: Is it always symptomatic? *AJR Am J Roentgenol* 2000;175(3):649-653.
35. Sharp RJ, Wade CM, Hennessy MS, Saxby TS: The role of MRI and ultrasound imaging in Morton's neuroma and the effect of size of lesion on symptoms. *J Bone Joint Surg Br* 2003;85(7):999-1005.
36. Rasmussen MR, Kitaoka HB, Patzer GL: Nonoperative treatment of plantar interdigital neuroma with a single corticosteroid injection. *Clin Orthop Relat Res* 1996;326:188-193.
37. Markovic M, Crichton K, Read JW, Lam P, Slater HK: Effectiveness of ultrasound-guided corticosteroid injection in the treatment of Morton's neuroma. *Foot Ankle Int* 2008;29(5):483-487.
38. Espinosa N, Seybold JD, Jankauskas L, Erschbamer M: Alcohol sclerosing therapy is not an effective treatment for interdigital neuroma. *Foot Ankle Int* 2011;32(6):576-580.
39. Gurdezi S, White T, Ramesh P: Alcohol injection for Morton's neuroma: A five-year follow-up. *Foot Ankle Int* 2013;34(8):1064-1067.
40. McCrory P, Bell S, Bradshaw C: Nerve entrapments of the lower leg, ankle and foot in sport. *Sports Med* 2002;32(6):371-391.
41. Title CI, Schon LC: Morton neuroma: Primary and secondary neurectomy. *J Am Acad Orthop Surg* 2008;16(9):550-557.
42. Womack JW, Richardson DR, Murphy GA, Richardson EG, Ishikawa SN: Long-term evaluation of interdigital neuroma treated by surgical excision. *Foot Ankle Int* 2008;29(6):574-577.
43. Johnson JE, Johnson KA, Unni KK: Persistent pain after excision of an interdigital neuroma: Results of reoperation. *J Bone Joint Surg Am* 1988;70(5):651-657.
44. Barrett SL, Rabat E, Buitrago M, Rascon VP, Applegate PD: Endoscopic decompression of intermetatarsal nerve for the treatment of Morton's entrapment: Multicenter retrospective review. *Open Journal of Orthopedics* 2012;2:19-24.
45. Villas C, Florez B, Alfonso M: Neurectomy versus neurolysis for Morton's neuroma. *Foot Ankle Int* 2008;29(6):578-580.
46. Barrett SL: Endoscopic nerve decompression. *Clin Podiatr Med Surg* 2006;23(3):579-595.
47. Shapiro SL: Endoscopic decompression of the intermetatarsal nerve for Morton's neuroma. *Foot Ankle Clin* 2004;9(2):297-304.
48. Zelent ME, Kane RM, Neese DJ, Lockner WB: Minimally invasive Morton's intermetatarsal neuroma decompression. *Foot Ankle Int* 2007;28(2):263-265.
49. Johnston EC, Howell SJ: Tension neuropathy of the superficial peroneal nerve: Associated conditions and results of release. *Foot Ankle Int* 1999;20(9):576-582.
50. Rosson GD, Dellon AL: Superficial peroneal nerve anatomic variability changes surgical technique. *Clin Orthop Relat Res* 2005;438:248-252.
51. Styf J, Morberg P: The superficial peroneal tunnel syndrome: Results of treatment by decompression. *J Bone Joint Surg Br* 1997;79(5):801-803.
52. Flanigan RM, DiGiovanni BF: Peripheral nerve entrapments of the lower leg, ankle, and foot. *Foot Ankle Clin* 2011;16(2):255-274.
53. Aktan Ikiz ZA, Ucerler H, Uygur M: Dimensions of the anterior tarsal tunnel and features of the deep peroneal nerve in relation to clinical application. *Surg Radiol Anat* 2007;29(7):527-530.
54. Dellon AL: Deep peroneal nerve entrapment on the dorsum of the foot. *Foot Ankle* 1990;11(2):73-80.
55. Beskin JL: Nerve entrapment syndromes of the foot and ankle. *J Am Acad Orthop Surg* 1997;5(5):261-269.
56. Seror P: Sural nerve lesions: A report of 20 cases. *Am J Phys Med Rehabil* 2002;81(11):876-880.
57. Yuebing L, Lederman RJ: Sural mononeuropathy: A report of 36 cases. *Muscle Nerve* 2014;49(3):443-445.
58. Fabre T, Montero C, Gaujard E, Gervais-Dellion F, Durandau A: Chronic calf pain in athletes due to sural nerve entrapment: A report of 18 cases. *Am J Sports Med* 2000;28(5):679-682.
59. Buschbacher RM: Sural and saphenous 14-cm antidromic sensory nerve conduction studies. *Am J Phys Med Rehabil* 2003;82(6):421-426.